

Case report

Open Access

Local recurrence and distant metastases 18 years after resection of the greater omentum hemangiopericytoma

Maciej Slupski*, Ilona Piotrowiak and Zbigniew Włodarczyk

Address: Department of Transplantation and General Surgery, Ludwik Rydygier Collegium Medicum in Bydgoszcz, Nicolaus Copernicus University in Torun, Poland

Email: Maciej Slupski* - maciejslupski@wp.pl; Ilona Piotrowiak - ilonapiotrowiak@wp.pl; Zbigniew Włodarczyk - zwlodar@yahoo.co.uk

* Corresponding author

Published: 6 June 2007

Received: 7 February 2007

World Journal of Surgical Oncology 2007, **5**:63 doi:10.1186/1477-7819-5-63

Accepted: 6 June 2007

This article is available from: <http://www.wjso.com/content/5/1/63>

© 2007 Slupski et al; licensee BioMed Central Ltd.

This is an Open Access article distributed under the terms of the Creative Commons Attribution License (<http://creativecommons.org/licenses/by/2.0>), which permits unrestricted use, distribution, and reproduction in any medium, provided the original work is properly cited.

Abstract

Background: Hemangiopericytoma occurs with increasing frequency in 5th decade of life and has prediction for retroperitoneum and extremities. A case of a local recurrence and metastases of hemangiopericytoma is described.

Case presentation: Recurrence of hemangiopericytoma in the greater omentum and the jejunal mesentery as well as metastases in the retroperitoneal space were diagnosed in a 61-year-old patient who had a hemangiopericytoma of the greater omentum excised 18 years before.

Conclusion: Because of the rarity of this disease and its typical clinical course associated with late recurrence and metastases, the authors decided to present this case emphasizing the necessity of systematic oncological follow-up after the end of treatment.

Background

Hemangiopericytoma is a tumor originating from the vascular pericytes of Zimmermann. Most frequently it occurs in patients aged 40 and above with its main localization in the retroperitoneum, pelvis and lower extremities [1-3], however, it may occur at any age in almost any part of body [4]. One of the typical features of this tumor is that both metastasis and recurrence could become apparent even after several years in remission [5-7].

We report the case of a local recurrence and metastases in the retroperitoneum infiltrating the liver and diaphragm in a 61-year-old patient operated on due to a hemangiopericytoma of the greater omentum 18 years before.

Case presentation

A 61-year-old patient was admitted to the Department of Transplantation and General Surgery with a tumor diag-

nosed in the left lumbar and retroperitoneal space. Eighteen years before he had been operated for a tumor of the greater omentum with histopathological diagnosis haemangiopericytoma omenti maioris, until now with no recurrence nor distant metastases were found.

On admission the patient was in good general condition with left lumbar pain and a mobile tumor in this area. Abdominal ultrasonography (US) and computed tomography (CT) revealed a retroperitoneum space tumor with suspected infiltration of the segment VII of the liver and diaphragm.

Laboratory investigation showed no abnormalities. The patient was qualified for surgical treatment. A tumor of 5 cm in diameter in the greater omentum tightly adjacent to a transverse colon (figure 1), a tumor of 1 cm in diameter in the jejunum mesentery (figure 2, arrow) and a tumor of

12 cm in diameter located in the retroperitoneal space and infiltrating the diaphragm and the segment VII of the liver were found. No other lesions were found in intraoperative US. The tumors of the greater omentum and of the jejunum mesentery were excised whereas the retroperitoneal space tumor was removed *en bloc* with the infiltrated part of the diaphragm and the segment VII of the liver (figure 3, and 4). The postoperative course proved uneventful. The patient was discharged from the hospital 7 days after the procedure in good general condition with a subsequent surgical follow-up recommended.

Histopathological examination of all the lesions showed haemangiopericytoma malignum. The patient remains under the Oncology Centre and our clinical follow-up and at present, 3 months after the procedure, is in good condition.

Discussion

Hemangiopericytomas represent less than 1% of all vascular neoplasms [8]. They are highly vascular, therefore could be revealed by angio-CT and angiography (for diagnosis, tumor size, relationship to other viscera, source of blood supply) as well as undergo preoperative transarterial embolization if necessary [3,5]. The tumors' medium size is 6.5 cm and they are encapsulated by a pseudocapsule [1,3]. There is no grading scale for hemangiopericytoma; its malignant potential is implied by histology and clinical behavior [5]. Hypervascularity is a contraindica-

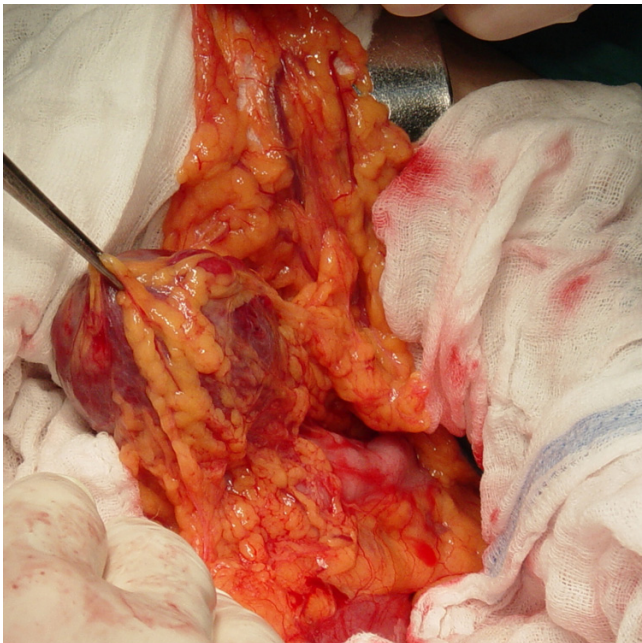


Figure 1
Tumor the greater omentum adjacent to a transverse colon in situ.

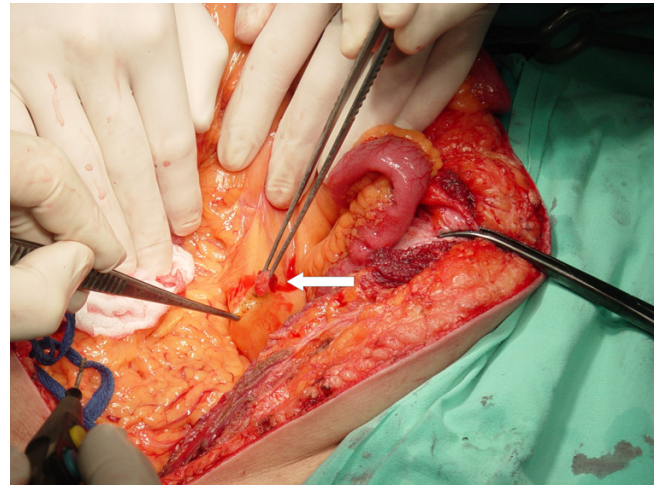


Figure 2
Tumor of the jejunum mesentery (arrow) in situ.

tion to a biopsy, therefore a histopathological diagnosis is established after an excision of the lesion. Potentially malignant tumors are characterized by 1 mitotic figure per 10 high-power field and moderate anaplasia. According to McMaster *et al.*, 25 of 32 (78%) malignant tumors, 6 of 16 (37.5%) borderline lesions and no benign tumors metastasised [6].

Metastases occur by hematogenous and lymphogenous routes affecting mainly the lung, liver, bones and regional lymph nodes [1,3,9,10]. Metastasis to pleura have also been reported [11]. Metastases occurring many years after excision of a primary lesion is typical of hemangiopericy-

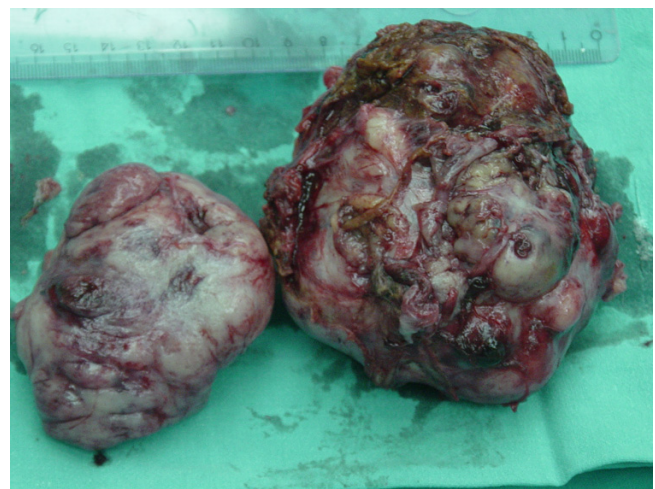

Figure 3
Retroperitoneal space tumor with the infiltrated part of the diaphragm and the segment VII of the liver – postoperative specimen.

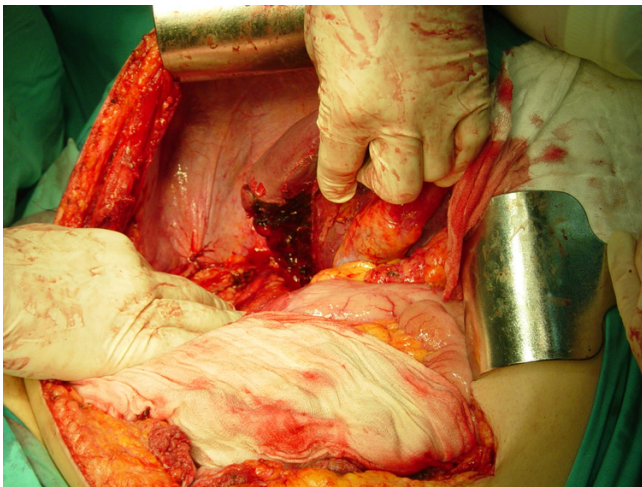


Figure 4
Site of organ removal.

toma: In our case it was 18 years. Multiple hepatic and bone metastases 12 years after an excision of a nose tumor have been reported [12]. McMaster *et al.*, reveal that metastases became apparent in 11% of patients with malignant tumors and 7% with borderline tumors after 5 years' remission [6]. Local recurrence is also common and precedes metastases in more than 2/3 of cases [1,13]. In two cases presented by Panda *et al.*, it occurred after 4 months in one patient and 22 years in another [7]. Therefore long-term follow-up is essential [6]. Hypercellularity, mitotic activity, anaplasia, necrosis and hemorrhage are reported to be associated with higher malignant potential [13].

Surgical resection with subsequent radiotherapy remains the treatment of choice for hemangiopericytoma. The role of preoperative angiography and tumor embolization is also emphasized in literature [3,5,6]. Survival rates vary: In a review of 106 cases of hemangiopericytoma, Enzinger *et al.*, reported 70% 10-year survival, whereas it was 50% 5-year survival according to other authors [1,10].

Late recurrence is common in other malignancies as well. According to Shen *et al.*, in primary cutaneous melanoma the mean disease-free interval after surgery was 182 months [14] whereas Briele *et al.*, report seven patients in whom local or regional recurrence occurred 11 to 23 years after first treatment of melanoma [15]. Another neoplasm after a treatment of which long-term follow-up is essential is medulloblastoma as recurrences after the Collins' risk period (i.e. age of a patient plus 9 months) have been noticed [16,17]. The average follow-up in case of rectal cancer surgical treatment is 2 years whereas research shows that local recurrence can become evident even after 5.8 years and systemic recurrence after 7.9 years [18].

Continued long-term follow-up in patients treated for above mentioned malignancies proves beneficial [15,17,19].

Conclusion

Every patient treated due to a malignant or borderline hemangiopericytoma should be under long-term oncological follow-up as the risk of recurrence and distant metastases even after many years is very high.

Competing interests

The authors declare that they have no competing interests.

Authors' contributions

MS conceived the idea for the study, participated in its design and coordination, analyzed the data, wrote the first draft of the manuscript.

IP conducted the literature review, was involved in data collection, analyzed the data, helped to draft the manuscript.

ZW participated in the study design and coordination, helped to draft the manuscript.

All authors read and approved the final version of the manuscript.

Acknowledgements

The written consent was obtained from the patient for publication of this case report.

References

1. Enzinger FM, Smith BH: **Hemangiopericytoma. An analysis of 106 cases.** *Hum Pathol* 1976, **7**:61-82.
2. Smith RT, Small WC, Mansour K: **Case report: hemangiopericytoma of the oesophagus.** *Br J Radiol* 1995, **68**:1031-1033.
3. Goldman S, Davidson A, Neal J: **Retroperitoneal and pelvic hemangiopericytomas: clinical, radiologic, and pathologic correlation.** *Radiology* 1988, **168**:13-17.
4. Stout AP: **Tumors featuring pericytes. Glomus tumor and hemangiopericytoma.** *Lab Invest* 1956, **5**:217-223.
5. Craven JP, Quigley TM, Bolen JW, Raker EJ: **Current management and clinical outcome of hemangiopericytomas.** *Am J Surg* 1992, **163**:490-493.
6. McMaster MJ, Soule EH, Ivins JC: **Hemangiopericytoma. A clinicopathologic study and long-term follow up of 60 patients.** *Cancer* 1975, **36**:2232-2244.
7. Panda A, Dayal Y, Singhal V, Pattnaik NK: **Hemangiopericytoma.** *Br J Ophth* 1984, **68**:124-127.
8. Sabini P, Josephson GD, Yung RT, Dolitsky JN: **Hemangiopericytoma presenting as a congenital midline nasal mass.** *Arch Otolaryngol Head Neck Surg* 1998, **124**:202-204.
9. Binder SC, Wolfe HJ, Deterling RA Jr: **Intraabdominal hemangiopericytoma: report of four cases and review of the literature.** *Arch Surg* 1973, **107**:536-543.
10. Felix EL, Wood DK, Das Gupta TK: **Tumors of the retroperitoneum.** In *Current problems in cancer* Edited by: Hickey RC, Clark RL, Benfield JR, Hurter R, Moertel CC, Shingleton W. Chicago: Year Book Medical; 1981:1-47.
11. Pandey M, Ahmed MI, Abraham EK, Sebastian P: **Recurrent Hemangiopericytoma metastasizing to pleura: A case report.** *Indian J Surg* 2002, **64**:183-185.

12. Dempke W, Firusian N: **Unusual course of hemangiopericytoma.** *Med Klin (Munich)* 1998, **93**:726-728.
13. Pandey M, Kothari KC, Patel DD: **Hemangiopericytoma. Current status, diagnosis and management.** *Eur J Surg Oncol* 1997, **23**:282-285.
14. Shen P, Guenther JM, Wanek LA, Morton DL: **Can elective lymph node dissection decrease the frequency and mortality rate of late melanoma recurrences?** *Ann Surg Oncol* 2000, **7**:114-119.
15. Briele HA, Beattie CV, Ronan SG, Chaudhuri PK, Das Gupta TK: **Late recurrence of cutaneous melanoma.** *Arch Surg* 1983, **118**:800-803.
16. King GA, Sagerman RH: **Late recurrence in medulloblastoma.** *Am J Roentgenol Radium Ther Nucl Med* 1975, **123**:7-12.
17. Nishio S, Morioka T, Takeshita I, Fukui M: **Medulloblastoma: Survival and late recurrence after the Collins' risk period.** *Neurosurg Rev* 1997, **20**:245-249.
18. Moore E, Heald RJ, Cecil TD, Sharpe GD, Sexton R, Moran BJ: **Almost all five year disease free survivors are cured following rectal cancer surgery, but longer term follow-up detects some late local and systemic recurrences.** *Colorectal Dis* 2005, **7**:403-5.
19. Koh HK, Sober AJ, Fitzpatrick TB: **Late recurrence (beyond ten years) of cutaneous malignant melanoma. Report of two cases and a review of the literature.** *JAMA* 1984, **251**:1859-1862.

Publish with **BioMed Central** and every scientist can read your work free of charge

"BioMed Central will be the most significant development for disseminating the results of biomedical research in our lifetime."

Sir Paul Nurse, Cancer Research UK

Your research papers will be:

- available free of charge to the entire biomedical community
- peer reviewed and published immediately upon acceptance
- cited in PubMed and archived on PubMed Central
- yours — you keep the copyright

Submit your manuscript here:
http://www.biomedcentral.com/info/publishing_adv.asp

