

Digital-image analysis of the left common carotid artery in human fetuses

M. Szpinda, P. Flisiński, M. Wiśniewski, M. Dombek, E. Krakowiak-Sarnowska

Department of Normal Anatomy, the Ludwik Rydygier Collegium Medicum in Bydgoszcz, the Nicolaus Copernicus University, Toruń, Poland

[Received 31 October 2007; Revised 16 May 2008; Accepted 16 May 2008]

The rate of growth of the left common carotid artery during gestation has not been sufficiently evaluated. The present study was performed on 128 spontaneously aborted human fetuses aged 15–34 weeks to compile normative data for the dimensions of the left common carotid artery at varying gestational ages. Using anatomical dissection, digital image analysis (system of Leica Q Win Pro 16) and statistical analysis (ANOVA, regression analysis), a range of measurements (length, original external diameter and volume) for the left common carotid artery during gestation was examined. No significant gender differences were found ($p > 0.05$). The growth curves of the best fit for the plot of each morphometric parameter against gestational age were generated. The lengths ranged from 14.82 ± 2.22 to 42.84 ± 4.32 mm, according to the linear model $y = -9.6918 + 1.5963x \pm 3.1706$ ($r = 0.95$; $p < 0.001$). The original external diameter increased from 0.72 ± 0.18 to 3.28 ± 0.40 mm, according to the linear function $y = -1.5228 + 0.1428x \pm 0.2749$ ($r = 0.95$; $p < 0.001$). The left common carotid artery-to-aortic root diameter ratio increased from 0.356 ± 0.062 to 0.480 ± 0.101 . The left common carotid artery-to-aortic arch diameter ratio increased from 0.447 ± 0.079 to 0.535 ± 0.113 . The volume ranged from 6.73 ± 4.06 to 369.30 ± 107.42 mm³ in accordance with the quadratic function $y = 344.8 - 41.001x + 1.254x^2 \pm 46.955$ ($R^2 = 0.87$). The parameters examined have clinical application in the early recognition of arterial abnormalities, especially aortic coarctation. (Folia Morphol 2008; 67: 186–192)

Key words: left common carotid artery, measurements, length, original external diameter, volume, regression analysis

INTRODUCTION

The common carotid arteries develop from both an elongation of the adjacent part of the aortic sac and the proximal part of the third embryonic aortic arches [14]. The left common carotid artery varies in origin more than the right one. According to Anson's examination [1] of 1000 adult cadavers it may arise from the aortic arch (69.4%), brachiobicarotid trunk (28.2%), left brachiocephalic trunk (1.3%),

bicarotid trunk (0.8%) and single arterial trunk (0.3%). The left common carotid artery ascends in the superior mediastinum until level with the left sternoclavicular joint (thoracic part) and then enters the neck, diverging laterally from behind the left sternoclavicular joint to the level of the thyroid cartilage's upper border (cervical part), where it divides into the left external and internal carotid arteries. High-resolution echocardiographic imaging is a safe

Table 1. Age, number and sex of the fetuses studied

Foetal age		Crown-rump length [mm]				Number	Sex	
Months	Weeks (Hbd-life)	Mean	SD	Min	Max		Male	Female
4	15	89.4	6.1	85.0	92.0	10	5	5
	16	103.7	6.1	95.0	106.0	7	3	4
5	17	114.9	8.2	111.0	121.0	6	4	2
	18	129.3	6.6	124.0	134.0	8	3	5
	19	142.7	7.7	139.0	148.0	6	3	3
	20	155.3	5.8	153.0	161.0	4	1	3
6	21	167.1	4.7	165.0	173.0	3	2	1
	22	178.1	6.9	176.0	186.0	7	4	3
	23	192.3	6.3	187.0	196.0	9	4	5
	24	202.9	5.7	199.0	207.0	11	6	5
7	25	215.2	4.8	211.0	218.0	7	5	2
	26	224.7	5.2	220.0	227.0	7	4	3
	27	234.1	4.3	231.0	237.0	4	0	4
	28	244.2	5.1	240.0	246.0	5	2	3
8	29	253.8	4.5	249.0	255.0	6	1	5
	30	262.7	3.1	260.0	264.0	6	5	1
	31	270.7	5.2	268.0	275.0	4	1	3
	32	281.4	3.7	279.0	284.0	5	4	1
9	33	290.3	6.1	286.0	293.0	9	4	5
	34	301.4	3.2	296.0	302.0	4	2	2
Total						128	63	65

and effective method of examining aortic arch branching in fetuses [10, 20]. Some echocardiographers [4, 6, 8] have stated that the left common carotid artery-to-aortic arch diameter ratio facilitates the prenatal diagnosis of aortic coarctation. According to some authors [3, 4] the left common carotid artery diameter was found to increase in linear fashion throughout the second and third trimesters.

There has hitherto been a paucity of quantitative anatomical data concerning the length and volume of the left common carotid artery. The present study was undertaken in order to construct a normal range for the morphometric features of the left common carotid artery during gestation.

Our objectives were set to examine the following:

- the normal values for the length, original external diameter and volume of the left common carotid artery at varying gestational ages;
- the growth curves for normal development of the parameters studied;
- the relative growth of the original external diameter of the left common carotid artery in relation to the aortic root diameter or aortic arch diameter;
- possible gender differences.

MATERIAL AND METHODS

The examinations were carried out on 128 human fetuses of both sexes (63 males, 65 females) from spontaneous abortions or stillbirths, cardiovascular abnormalities having been excluded at necropsy. Foetal ages ranged from 15 to 34 weeks of gestation (Table 1). The present study was approved by the University Research Ethic Committee (KB/217/2006). Developmental age was determined on the basis of the following criteria:

- gestational age based on crown-to-rump length [5];
- known date of the beginning of the last normal menstrual period;
- in some cases corrections regarding foetal age were established by measuring their humeral and femoral bones using USG equipment [17].

Fetuses were grouped into six monthly cohorts, corresponding to the 4th – 9th months of gestation. The arterial bed was filled with white latex LBS 3060, without over-distension of the perfused vessels, through a catheter Stericath (diameter of 0.5–1.0 mm), which was introduced by lumbar access into the abdominal aorta. The foetal artery filling was performed under a controlled pressure of 50–60 mm Hg using a syringe infusion pump SEP 11S. All specimens

were immersed in 10% neutral formalin solution for 20–24 months for preservation. Dissection of the aortic arch and its branches was performed according to standard autopsy techniques under 10-fold magnification using a stereoscope with Huygens ocular. In each foetus the left common carotid artery *in situ* with the millimetre scale was placed perpendicular to the optical lens axis, afterwards recorded using a camera Nikon Coolpix 8400 and then digitalised to JPEG images. Next, digital pictures of the left common carotid artery underwent quantitative analysis using a digital image analysis system of Leica QWin Pro 16 (Cambridge), which automatically estimated the length, original external diameter and volume of the marked artery. Automatic measurements of the parameters examined were derived by assuming that the filled arteries were circular in cross-section and therefore constituted a flexible cylinder.

For each foetus the following seven measurements and calculations were made:

- 1) the largest original external diameter of the aortic root [mm], at the level of the aortic valve annulus;
- 2) the external diameter of the aortic arch [mm], distal to the left common carotid origin (i.e. transverse aortic diameter);
- 3–5) the length, original external diameter and volume of the left common carotid artery;
- 6) the left common carotid artery-to-aortic root diameter ratio;
- 7) the left common carotid artery-to-aortic arch diameter ratio.

The length, original external diameter and volume of the left common carotid artery were correlated to foetal age so as to establish their growth. Finally, the results obtained were evaluated by the one-way ANOVA test for unpaired data and the post-hoc RIR Tukey test. Regression analysis was used to derive the line of best fit for the length, original external diameter and volume against gestational age. Correlation coefficients (r) between the length or original external diameter and foetal age, and coefficient of determination (R^2) between volume and foetal age were estimated. Because of the different sizes of the specimens, we calculated the ratio between the original external diameter of the left common carotid artery and that of the aortic root (the left common carotid artery-to-aortic root diameter ratio) or the aortic arch (the left common carotid artery-to-aortic arch diameter ratio).

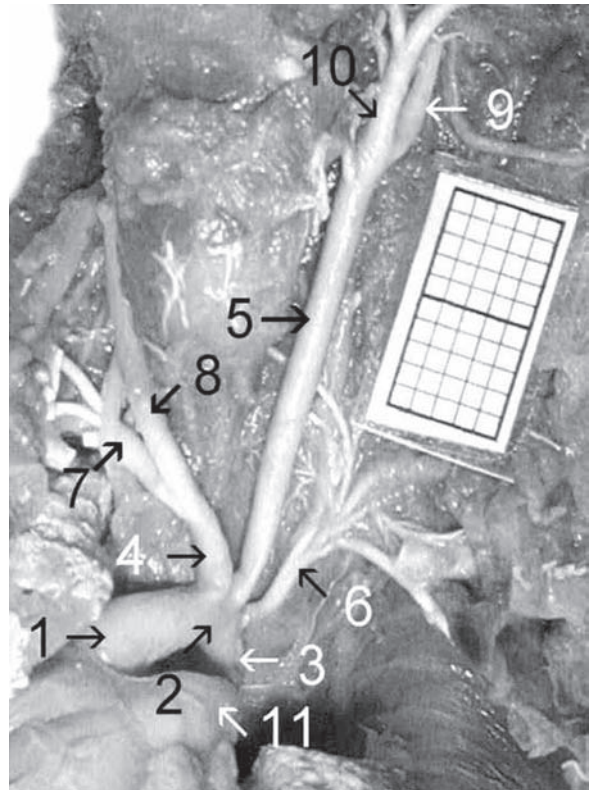


Figure 1. The usual branching of the aortic arch (type I of Anson) in a male foetus aged 20 weeks: 1 — ascending aorta, 2 — aortic arch, 3 — aortic isthmus, 4 — brachiocephalic trunk, 5 — left common carotid artery, 6 — left subclavian artery, 7 — right subclavian artery, 8 — right common carotid artery, 9 — left internal carotid artery, 10 — left external carotid artery, 11 — pulmonary trunk.

RESULTS

In the material under examination the left common carotid artery originated from the highest part of the aortic arch (Fig. 1), between the brachiocephalic trunk and the left subclavian artery in 79.39% of the individuals (49 males, 52 females). In the remaining 20.61% of cases (14 males, 13 females) it arose from the brachio-bicarotid trunk (Fig. 2). There were no high or low types of division of the left common carotid artery in the fetuses studied.

Statistical analysis of the features of the left common carotid artery examined did not show gender differences ($p > 0.05$). The morphometric values obtained have therefore been presented, without regard to sex, in Table 2. Both the length and original external diameter of the left common carotid artery revealed a proportional increase in values with advanced foetal age. The values of the length of the left common carotid artery ranged from 14.82 ± 2.22 mm for the 4-month group to 42.84 ± 4.32 mm for group in the 9th month of gestation.

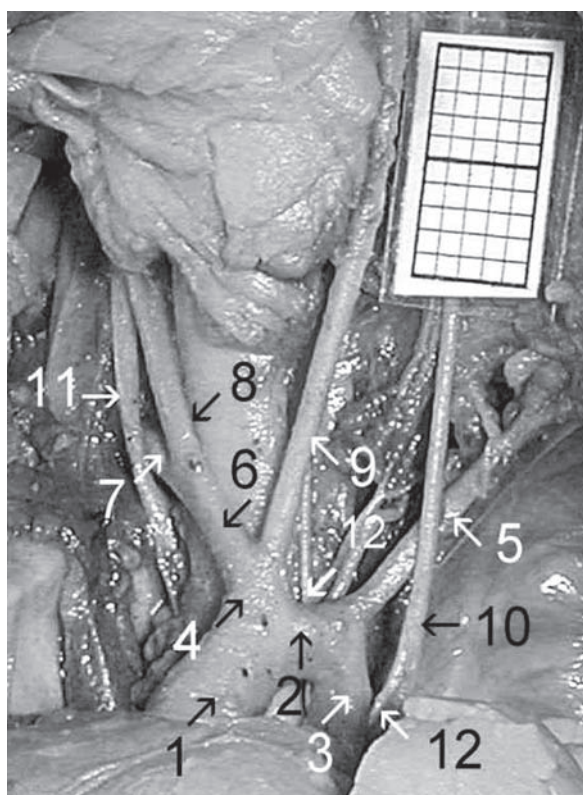


Figure 2. Reduction to two derived branches of the aortic arch (type II of Anson) in a female foetus aged 25 weeks: 1 — ascending aorta, 2 — aortic arch, 3 — aortic isthmus, 4 — brachio-bica-rotid trunk, 5 — left subclavian artery, 6 — brachiocephalic trunk, 7 — right subclavian artery, 8 — right common carotid artery, 9 — left common carotid artery, 10 — left vagus nerve, 11 — right vagus nerve, 12 — left recurrent laryngeal nerve.

The length of the left common carotid artery in relation to foetal age in weeks increased according to the linear function $y = -9.6918 + 1.5963 x \pm 3.1706$

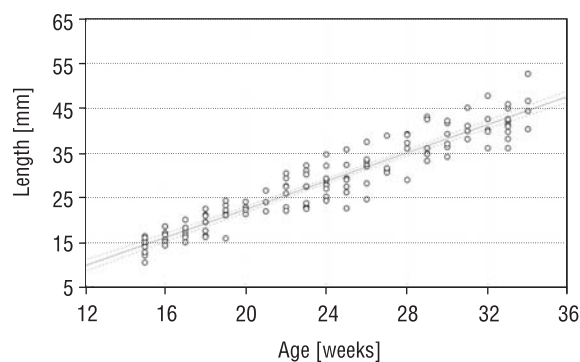


Figure 3. Regression line for the length (y) of the left common carotid artery versus foetal age (x); $y = -9.6918 + 1.5963 x \pm 3.1706$ ($r = 0.95$, $p < 0.001$).

(Fig. 3). The values for the original external diameter of the left common carotid artery ranged from 0.72 ± 0.18 to 3.28 ± 0.40 mm for the 4 and 9 month groups, respectively. The original external diameter of the left common carotid artery was dependent on foetal age in weeks according to the linear function $y = -1.5228 + 0.1428 x \pm 0.2749$ (Fig. 4). Positive correlation coefficients between length or original external diameter and foetal age were statistically significant ($p < 0.001$) and reached the value $r = 0.95$.

Parallel to the absolute increase in the values of the original external diameter of the left common carotid artery, its two relative diameters increased with advancing foetal age (Table 3). In the age range examined the left common carotid artery-to-aortic root diameter ratio increased from 0.356 ± 0.062 to 0.480 ± 0.101 . The left common carotid artery-to-aortic arch diameter ratio also increased from

Table 2. Block scheme of the statistical analysis of the left common carotid artery parameters

Foetal age [month]	n	Length [mm] (mean \pm SD)	Original external diameter [mm] (mean \pm SD)	Volume [mm ³] (mean \pm SD)
4	17	14.82 \pm 2.22 ↓ ($p < 0.01$)	0.72 \pm 0.18 ↓ ($p < 0.01$)	6.73 \pm 4.06 ↓ ($p > 0.05$)
5	24	19.72 \pm 2.88 ↓ ($p < 0.001$)	1.13 \pm 0.19 ↓ ($p < 0.001$)	21.22 \pm 9.55 ↓ ($p < 0.05$)
6	30	26.93 \pm 3.42 ↓ ($p < 0.001$)	1.75 \pm 0.36 ↓ ($p < 0.001$)	67.91 \pm 30.91 ↓ ($p < 0.01$)
7	23	32.03 \pm 4.71 ↓ ($p < 0.001$)	2.23 \pm 0.37 ↓ ($p < 0.001$)	130.68 \pm 55.27 ↓ ($p < 0.001$)
8	21	39.37 \pm 3.91 ↓ ($p < 0.001$)	2.85 \pm 0.40 ↓ ($p < 0.05$)	259.06 \pm 81.47 ↓ ($p < 0.001$)
9	13	42.84 \pm 4.32	3.28 \pm 0.40	369.30 \pm 107.42

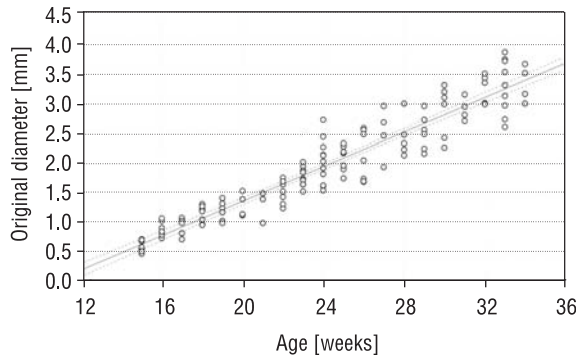


Figure 4. Regression line for the original external diameter (y) of the left common carotid artery versus foetal age (x); $y = -1.5228 + 0.1428x \pm 0.2749$ ($r = 0.95$, $p < 0.001$).

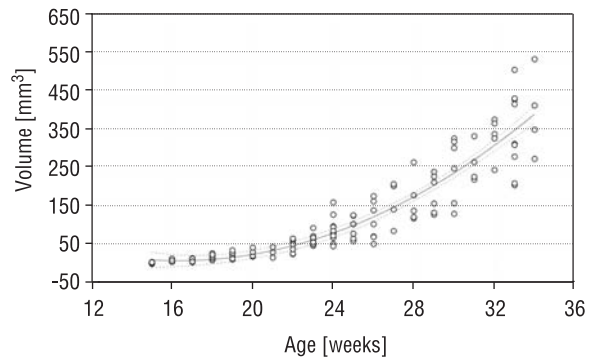


Figure 5. Regression line for the volume (y) of the left common carotid artery versus foetal age (x); $y = 344.8 - 41.001x + 1.254x^2 \pm 46.955$ ($R^2 = 0.87$).

Table 3. Block scheme of the statistical analysis of the relative diameters of the left common carotid artery

Foetal age [month]	n	Aortic root diameter [mm] (mean \pm SD)	Aortic arch diameter [mm] (mean \pm SD)	Left common carotid artery-to-aortic root diameter ratio	Left common carotid artery-to-aortic arch diameter ratio
4	17	2.02 \pm 0.26 \downarrow ($p < 0.001$)	1.61 \pm 0.24 \downarrow ($p < 0.001$)	0.356 \pm 0.062 \downarrow ($p > 0.05$)	0.447 \pm 0.079 \downarrow ($p > 0.05$)
5	24	2.94 \pm 0.49 \downarrow ($p < 0.001$)	2.32 \pm 0.45 \downarrow ($p < 0.001$)	0.384 \pm 0.121 \downarrow ($p < 0.05$)	0.487 \pm 0.081 \downarrow ($p < 0.05$)
6	30	3.96 \pm 0.57 \downarrow ($p < 0.001$)	3.23 \pm 0.45 \downarrow ($p < 0.001$)	0.442 \pm 0.092 \downarrow ($p > 0.05$)	0.541 \pm 0.064 \downarrow ($p > 0.05$)
7	23	4.91 \pm 0.47 \downarrow ($p < 0.001$)	4.10 \pm 0.42 \downarrow ($p < 0.001$)	0.454 \pm 0.111 \downarrow ($p > 0.05$)	0.543 \pm 0.098 \downarrow ($p > 0.05$)
8	21	6.11 \pm 0.50 \downarrow ($p < 0.01$)	5.41 \pm 0.47 \downarrow ($p < 0.001$)	0.466 \pm 0.098 \downarrow ($p > 0.05$)	0.526 \pm 0.107 \downarrow ($p > 0.05$)
9	13	6.84 \pm 0.63	6.13 \pm 0.49	0.480 \pm 0.101	0.535 \pm 0.113

0.447 \pm 0.079 to 0.535 \pm 0.113 for the 4 and 9 month groups respectively. A significant increase in both the ratios was observed between the 5 and 6 month groups only ($p < 0.05$). The values of the volume of the left common carotid artery ranged from 6.73 \pm 4.06 mm³ for the 4th month to 369.30 \pm 107.42 mm³ for the 9th month of gestation. The volumetric growth of the left common carotid artery generated the quadratic function $y = 344.8 - 41.001x + 1.254x^2 \pm 46.955$ (Fig. 5). The coefficient of determination between volume and foetal age was statistically significant ($p < 0.001$) and reached the value $R^2 = 0.87$.

DISCUSSION

Reference data for the dimensions of the left common carotid artery, as determined using both

autopsy study and echocardiographic imaging, are scarce for human foetuses. In this anatomical study the digital image analysis system of Leica Q Win 16 Pro was used to provide normal morphometric values for the left common carotid artery at gestational ages ranging from 15 to 34 weeks. A particular strength of this study is the large number of normal specimens used to generate the growth curves. It should be noted that Flisiński et al. [3] have provided measurements (length, original external diameter and volume) of the common carotid arteries for foetuses aged 4–9 months but without growth curves for the normal growth of the parameters studied. The growth curves for the normal development of the left common carotid artery dimensions have not previously been reported in the professional literature. From the present data, growth of the length

and original external diameter appears to be linearly related to gestational age. Plots showing both the length and original external diameter of the left common carotid artery were modelled on the linear functions $y = -9.6918 + 1.5963 x \pm 3.1706$ and $y = -1.5228 + 0.1428 x \pm 0.2749$ respectively. Moreover, correlation coefficients between these parameters and foetal age were very high ($r = 0.95$) and statistically significant ($p < 0.001$). Flisiński et al. [3] reported that the values of the length and original external diameter of the left common carotid artery ranged from 15.28 ± 2.29 to 44.81 ± 6.29 mm and from 0.84 ± 0.14 to 3.13 ± 0.40 mm respectively. However, in their material the correlation coefficients between length or original external diameter and gestational age were much lower ($r_1 = 0.87$ for length, $r_2 = 0.84$ for diameter) in comparison with our results ($r = 0.95$). Machii and Becker [7] showed an increase in the external diameter of the left common carotid artery from 3.4 ± 0.7 to 5.9 ± 0.5 mm in 19 specimens aged 0–4 years. Hornberger et al. [4] demonstrated that the internal diameter of the left common carotid artery was found to increase proportionally throughout the second and third trimesters. Morrow et al. [8] performed echocardiographic measurements of the internal diameter of the left common carotid artery in 14 neonates with isolated coarctation and in 14 normal control neonates. All neonates with coarctation demonstrated larger diameters (3.4 ± 0.6 mm) than control subjects (2.6 ± 0.4 mm; $p < 0.001$).

In the present study, the ratios of the left common carotid artery diameter to aortic root diameter or to aortic arch diameter showed a trend towards increase throughout gestation. The left common carotid artery-to-aortic root diameter ratio increased from 0.356 ± 0.062 to 0.480 ± 0.101 . In turn, developmental growth of the left common carotid artery-to-aortic arch diameter ratio from 0.447 ± 0.079 to 0.535 ± 0.113 was observed. It should, however, be noted that a statistically significant increase in both the ratios was found only between the 5 and 6 month groups ($p < 0.05$). Our findings confirmed a relative increase of the left common carotid artery diameter with advancing foetal age. These results correspond to the observations of Machii and Becker [7], where the external diameter of the left common carotid artery divided by that of the descending aorta increased from 0.50 ± 0.09 to 0.61 ± 0.07 in specimens aged 0–4 years.

In our opinion, the relative increase of the left common carotid artery diameter resulted from the

increase in the proportion of blood received by the human brain as foetal age advances. Rudolph and Heymann [13] held that in an animal model (lambs) the growth of the arterial diameter is proportional to the amount of blood carried. A similar flow therefore produces vessels of similar diameter. According to some authors [4, 6, 8] the left common carotid artery-to-aortic arch diameter ratio might assist in the early recognition of aortic arch abnormalities. Lappen et al. [6] and Morrow et al. [8] have shown that in normal infants the ratio of the left common carotid artery diameter to that of the aortic arch is 0.48 ± 0.08 , whereas in cases of infantile coarctation the same ratio is 0.96 ± 0.18 . The diameters of the left common carotid artery, the left subclavian artery and the aortic arch were essentially equal in coarctation patients. In contrast, in the normal neonate the diameters of the left common carotid and left subclavian arteries were approximately 50% of the aortic arch diameter. In the material of Hornberger et al. [4] the left common carotid artery-to-aortic arch diameter ratio reached the value 0.77 ± 0.05 for coarctation versus 0.48 ± 0.08 for normal fetuses. Dodge-Khatami et al. [2] demonstrated that the ratio of the aortic arch diameter at level of the left subclavian artery to the distance between the left common carotid and left subclavian arteries was significantly smaller in patients with coarctation. This ratio, which they propose as the carotid-subclavian artery index, is a simple non-invasive screening parameter that may be useful in unstable patients or in those with a patent ductus arteriosus, in which coarctation may be overlooked.

Flisiński et al. [3] reported that the volume of the left common carotid artery ranged from 9.32 ± 4.21 mm³ in fetuses aged 4 months to 358.70 ± 142.40 mm³ for those in the 9th month of gestation. The values obtained by these authors were in close relation to our findings, because in the material under examination the left common carotid artery volume increased from 6.73 ± 4.06 to 369.30 ± 107.42 mm³. The regression equation for the volume of the left common carotid artery in mm³, modelled as a function of gestational age in terms of weeks, was $y = 344.8 - 41.001 x + 1.254 x^2 \pm 46.955$. This quadratic function was the best model for the volumetric growth of the left common carotid artery, because the coefficient of determination between volume and foetal age reached the value $R^2 = 0.87$. Szpinda et al. [15, 17–19] has also demonstrated that volumetric growth of the different foetal arteries proceeds according to the quadratic function.

No statistically significant gender differences for the dimensions of the left common carotid artery were observed in this study. In this respect the present results are in close accordance with previous studies concerning measurements of the dimensions of the aortic and great pulmonary arterial pathways in human fetuses [15–19]. Poutanen et al. [11] found slight differences in aortic measurements between genders in children and young adults, these being greater in males than in females. Nevertheless, the values were similar in both genders when indexed to BSA. In children growth of the aortic root diameter has been found to be independent of gender [9, 12].

This study has demonstrated quantitative analysis of the left common carotid artery during gestation. The parameters examined provide morphometric reference information for future studies on this subject and have a clinical application in the early recognition of aortic coarctation.

REFERENCES

1. Anson BI (1971) Thoracic cavity and its contents. In: Anson BI, Mc Vay Ch eds. *Surgical anatomy*. Vol. 1. WB Saunders Company, Philadelphia, pp. 408–412.
2. Dodge-Khatami A, Ott S, Di Bernardo S, Berger F (2005) Carotid-subclavian artery index: new echocardiographic index to detect coarctation in neonates and infants. *Ann Thorac Surg*, 80: 1652–1657.
3. Flisiński P, Szpinda M, Flisiński M (2005) Variability and morphometric parameters of the carotid arteries in human fetuses. *Med Biol Sci*, 19: 147–151.
4. Hornberger LK, Weintraub RG, Pesonen E, Murilo-Olivas A, Simpson IA, Sahn C, Hagen-Ansert S, Sahn DJ (1992) Echocardiographic study of the morphology and growth of the aortic arch in the human fetus. Observations related to the prenatal diagnosis of coarctation. *Circulation*, 86: 741–747.
5. Iffy L, Jakobovits A, Westlake W, Wingate MB, Caterini H, Kanofsky P, Menduke H (1975) Early intrauterine development: I. The rate of growth of Caucasian embryos and fetuses between the 6th and 20th weeks of gestation. *Pediatrics*, 56: 173–186.
6. Lappen RS, Muster AJ, Duffy CE, Berdussis K, Paul MH (1986) Predictability of coarctation of the aorta from the degree of transverse aortic arch hypoplasia: an echocardiographic-angiographic correlation. In: Doyle EF, Engle MA, Persony WM, Rashkind WJ, Talner NS eds. *Pediatric cardiology*. Springer, New York, pp. 172–175.
7. Machii M, Becker AE (1997) Morphologic features of the normal aortic arch in neonates, infants, and children pertinent to growth. *Ann Thorac Surg*, 64: 511–515.
8. Morrow WR, Huhta LC, Murphy DJ, McNamara DG (1986) Quantitative morphology of the aortic arch in neonatal coarctation. *J Am Coll Cardiol*, 8: 616–620.
9. Nidorf SM, Picard MH, Triulzi MO, Thomas JD, Newell J, King ME, Weyman AE (1992) New perspectives in the assessment of cardiac chamber dimensions during development and adulthood. *J Am Coll Cardiol*, 19: 983–988.
10. Nomiyama M, Ueda Y, Toyota Y, Kawano H (2002) Fetal aortic isthmus growth and morphology in late gestation. *Ultrasound Obstet Gynecol*, 19: 153–157.
11. Poutanen T, Tikanoja T, Sairanen H, Jokinen E (2003) Normal aortic dimensions and flow in 168 children and young adults. *Clin Physiol Funct Imag*, 23: 224–229.
12. Roman MJ, Devereux RB, Kramer-Fox R, O'Loughlin J (1989) Two-dimensional echocardiographic aortic root dimensions in normal children and adults. *Am J Cardiol*, 64: 507–512.
13. Rudolph AM, Heymann MA (1970) Circulatory changes during growth in the fetal lamb. *Circ Res*, 26: 289–299.
14. Sadler TW (1993) *Langman's medical embryology*. Med Tour Press International, Warsaw, pp. 207–219.
15. Szpinda M, Flisiński P, Elminowska-Wenda G, Flisiński M, Krakowiak-Sarnowska E (2005) The variability and morphometry of the brachiocephalic trunk in human fetuses. *Folia Morphol*, 64: 309–314.
16. Szpinda M, Brazis P, Elminowska-Wenda G, Wiśniewski M (2006) Morphometric study of the aortic and great pulmonary arterial pathways in human fetuses. *Ann Anat*, 188: 25–31.
17. Szpinda M, Szwesta A, Szpinda E (2007) Morphometric study of the ductus arteriosus during human development. *Ann Anat*, 189: 47–52.
18. Szpinda M (2007) Morphometric study of the ascending aorta in human fetuses. *Ann Anat*, 189: 465–472.
19. Szpinda M (2007) Morphometric study the brachio-bicarotid trunk in human fetuses. *Ann Anat*, 189: 569–574.
20. Ursell PC, Byrne JM, Fears TR, Strobino BA, Gersony WM (1991) Growth of the great vessels in the normal human fetus and in the fetus with cardiac defects. *Circulation*, 84: 2028–2033.